

# Simple Limbal Epithelial Transplantation in Acid Injury and Severe Dry Eye

SUDESH KUMAR ARYA<sup>1</sup>, ANUBHA BHATTI<sup>2</sup>, AMIT RAJ<sup>3</sup>, RAVI KANT BAMOTRA<sup>4</sup>

## ABSTRACT

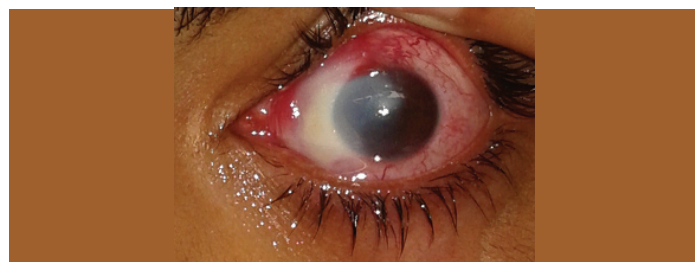
The epithelial cells of cornea constantly undergo renewal and regeneration and the stem cells responsible for renewal resides within basal epithelium at the limbus in palisades of Vogt. Simple limbal epithelial transplantation (SLET) is a simplified technique for limbal stem cell deficiency and it combines the benefits of both conjunctival limbal autografting and cultivated limbal epithelial transplantation by being single-stage and utilizing minimal donor tissue. We will be discussing two cases of ocular surface disorder which were managed successfully by new technique simple limbal epithelial transplantation. Two patients one with unilateral Limbal Stem Cell Deficiency (LSCD) following acid injury and other with bilateral LSCD due to severe dry eye underwent limbal epithelial transplantation using the SLET method after taking prior consent for the procedure. Success was termed complete when a completely epithelialized, avascular and stable corneal surface was seen. The follow up examinations were done on first day, at 1 week, 2 weeks, 4 weeks and at 3 months after the surgery. A completely epithelialised, avascular and stable corneal surface was achieved by 4 weeks in both patients. Simple limbal epithelial transplantation is a new technique which is simple, cheap and easily affordable and it has decreased the dependence on stem cell laboratory.

**Keywords:** Stem cell transplant, Chemical injury, Ocular surface disorder

## CASE REPORT

### Case 1

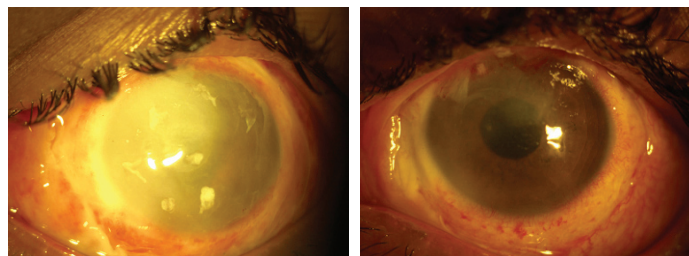
A 14-year-old male student with hydrochloric acid injury in his left eye presented after a period of one month with visual acuity-hand movement close to face (HMCF), limbal ischemia of 4 clock hours, conjunctival involvement of 33%, epithelial defect 8×6mm and diffuse stromal haze. So diagnosis of Grade III Chemical injury was made according to Dua Classification [1] [Table/Fig-1]. Patient underwent limbal epithelial transplantation using the simple limbal epithelial transplantation (SLET) method.



**[Table/Fig-1]:** Slit lamp photograph of left eye of patient (case 1) showing limbal ischemia of 4 clock hours, conjunctival involvement of 33%, epithelial defect 8×6mm and diffuse stromal haze.

A 2×2 mm strip of donor limbal tissue was obtained from superior limbus of right eye /healthy eye. In the recipient eye, a 360 degree peritomy was performed all along about 3-4 mm from the limbus. Human Amniotic Membrane (hAM) graft was taken from seronegative mother after cesarean section & graft was placed over the bared ocular surface and secured with fibrin glue. The 2×2mm graft tissue was held with Lim's forceps and divided into 10 pieces with 15° surgical blade under 15x magnification. The small graft pieces then were placed over the amniotic membrane. The transplants were also fixed in place with fibrin glue. A soft bandage contact lens was placed on the recipient eye. Patient was prescribed moxifloxacin 0.3% eye drops four times a day for 1 week, prednisolone acetate 1% eye drops six times a day tapered weekly over 6 weeks and carboxymethyl cellulose 0.5% eye drops in the recipient eye. Patient was seen on day 1, 7, 14, 1 month, 3-months and at 6 months interval thereafter.

A completely epithelialised, avascular and stable corneal surface was achieved by four weeks. Best corrected visual acuity improved from HMCF to 20/20 by six weeks [Table/Fig-2,3]. The fibrin glue on the ocular surface had disintegrated by the end of the first postoperative week and the hAM disintegrated gradually over six weeks. The transplants remained in place and became progressively transparent over time.

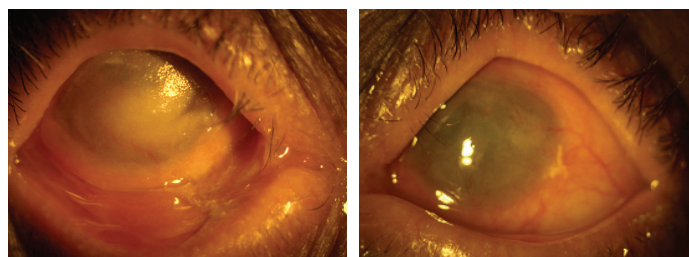


**[Table/Fig-2]:** Slit lamp photograph showing bandage contact lens and amniotic membrane in place with limbal stem cells distributed over corneal surface at postoperative day 1 (case 1).

**[Table/Fig-3]:** Slit lamp photograph showing bandage contact lens still in place with remnant of amniotic membrane superiorly at 1 month (case 1). Visual acuity was 20/25.

### Case 2

A 63-year-old female presented with ocular surface disease with severe dry eye in both eyes with primary open angle glaucoma [Table/Fig-4,5]. Patient underwent simple limbal epithelial transplantation



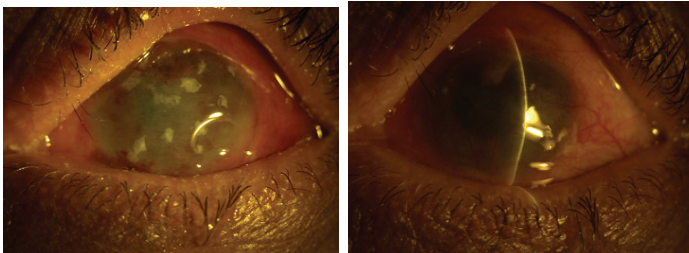
**[Table/Fig-4]:** Slit lamp photograph of right eye of patient (case 2) showing keratinization of cornea & symblepharon formation.

**[Table/Fig-5]:** Slit lamp photograph of left eye of patient (case 2) showing keratinization & vascularisation of cornea.

in the left eye. In this case due to bilateral involvement of eye, donor tissue was taken from preserved cadaveric donor cornea. All other steps of surgery were similar.

Patient was also prescribed moxifloxacin 0.3% eye drops, prednisolone acetate 1% eye drops and carboxymethyl cellulose 0.5% eye drops in the recipient eye.

A completely epithelialised and stable corneal surface was achieved in left eye by 4 weeks in this patient. Best corrected visual acuity improved from light perception to hand movements close to face [Table/Fig-6,7]. Visual acuity in this case improved only to hand movements close to face as patient had underlying optic atrophy which was detected after surgery when ocular surface became clear.



**[Table/Fig-6]:** Slit lamp photograph showing limbal stem cells distributed over corneal surface with bandage contact lens and amniotic membrane at postoperative day1 (case 2).

**[Table/Fig-7]:** Slit lamp photograph showing clear corneal surface postoperatively at 1 month (case 2).

## DISCUSSION

The corneal stem cell niche is believed to be located at the limbus, in the *palisades of Vogt* [2]. Davanger and Evensen, in 1971, first proposed the concept that epithelial cells in the limbal region are involved in the renewal of corneal epithelium [3]. Limbal stem cell deficiency is described as vascularization, keratinization, corneal scarring and corneal opacification caused by severe damage to cell repair mechanisms of the limbal region [4].

Sangwan et al., introduced a technique simple limbal epithelial transplantation for total limbal stem cell deficiency following ocular surface burns. This study included six adult patients; one patient of blast injury, 4 patients of alkali burns and one patient of acid injury. A completely epithelialised, avascular and stable corneal surface was seen in all recipient eyes by 6 weeks and visual acuity improved from 20/200 to 20/60 or better in four (66.6%) eyes. Results of two cases done at our center were consistent with this study. A stable corneal surface was seen by four weeks in our study and visual acuity improved to 20/20 in case of acid injury [5].

There has been a case report of in vivo expansion of autologous limbal stem cell using simple limbal epithelial transplantation for treatment of limbal stem cell deficiency secondary to accidental alkali injury in a 20-year-old male. At two years follow-up, the

patient's ocular surface is stable with improvement of visual acuity to 20/25 post SLET [6].

There has been another case report of successful autologous simple limbal epithelial transplantation in a three-year-old child sustaining ocular surface burns following accidental lime injury. At one year follow-up, visual acuity improved to 20/80 after SLET and patient continues to maintain avascular and epithelialised corneal surface [7].

A study reported results of SLET using a double layered cryopreserved amniotic membrane graft for the management of unilateral limbal stem cell deficiency. At mean follow up of seven months, regular corneal epithelium and quiet ocular surface were obtained in all patients by a median of four weeks. Our cases also showed stable and regular corneal epithelium by four weeks [8].

There have been only 2 series and 2 case reports available in literature till now but none of the study showed successful use of SLET in severe dry eye. The second patient, despite having dry eye responded very well to the treatment, as the patient was prescribed frequent instillation of carboxymethylcellulose 1% solution to take care of inadequate tears production. The allograft in SLET has not been used by any authors as per literature. Due to the bilaterality of the disease, the graft tissue containing limbal stem cells was taken from the cadaveric cornea. No similar cases of SLET have been reported in literature using cadaveric tissue.

## CONCLUSION

Simple limbal epithelial transplantation is a newer technique which is simple, easily affordable and it does not need stem cell laboratory for cultivation of limbal epithelial cells. As it is easily adaptable surgical technique, it can be repeated at different centres across the world.

## REFERENCES

- [1] Dua HS, King AJ, Joseph A. A new classification of ocular surface burns. *Br J Ophthalmol.* 2001;85:1379-83.
- [2] Schlotzer-Schrehardt U, Kruse FE. Identification and characterisation of limbal stem cells. *Exp Eye Res.* 2005;81:247-64.
- [3] Davanger M, Evensen A. Role of pericorneal papillary structure in renewal of corneal epithelium. *Nature.* 1971;229:560-61.
- [4] Fernandes M, Sangwan VS, Rao SK, Basti S, Sridhar MS, Bansal AK, et al. Limbal stem cell transplantation. *Indian J Ophthalmol.* 2004;52:5-22.
- [5] Sangwan VS, Basu S, MacNeil S, Balasubramanian D. Simple limbal epithelial transplantation (SLET): A novel surgical technique for the treatment of unilateral limbal stem cell deficiency. *Br J Ophthalmol.* 2012;96:931-34.
- [6] Lal I, Panchal BU, Basu S, Sangwan VS. In-vivo expansion of autologous limbal stem cell using simple limbal epithelial transplantation for treatment of limbal stem cell deficiency. *BMJ Case Rep.* 2013;2013:pil: bcr2013009247.
- [7] Bhalekar S, Basu S, Lal I, Sangwan VS. Successful autologous simple limbal epithelial transplantation (SLET) in previously failed paediatric limbal transplantation for ocular surface burns. *BMJ Case Rep.* 2013;2013:pil: bcr2013009888.
- [8] Amescua G, Atallah M, Nikpoor N, Galor A, Perez VL. Modified simple limbal epithelial transplantation using cryopreserved amniotic membrane for unilateral limbal stem cell deficiency. *Am J Ophthalmol.* 2014;158(3):469-75.

### PARTICULARS OF CONTRIBUTORS:

1. Professor, Department of Ophthalmology, Government Medical College and Hospital, Chandigarh, Punjab, India.
2. Assistant Professor, Department of Ophthalmology, Shri Guru Ram Das Institute of Medical Sciences & Research, Amritsar, Punjab, India.
3. Assistant Professor, Department of Ophthalmology, Government Medical College and Hospital, Chandigarh, Punjab, India.
4. Senior Resident, Department of Ophthalmology, Government Medical College and Hospital, Chandigarh, Punjab, India.

### NAME, ADDRESS, E-MAIL ID OF THE CORRESPONDING AUTHOR:

Dr. Anubha Bhatti,  
H.NO. 3024, Sector- 37/D, Chandigarh-160036, Punjab, India.  
E-mail: scorpiodoc9@gmail.com

FINANCIAL OR OTHER COMPETING INTERESTS: None.

Date of Submission: Feb 04, 2016  
Date of Peer Review: Feb 23, 2016  
Date of Acceptance: Apr 07, 2016  
Date of Publishing: Jun 01, 2016